

Removing brain cancer using non-labelling, quantitative optical imaging

Dr Xingde Li of Johns Hopkins University, Baltimore, and his collaborator **Dr Alfredo Quiñones-Hinojosa** of the Mayo Clinic, Florida, are giving a new lease of life to a biological imaging method developed nearly 30 years ago. By combining the properties of this method with the physiological properties of cancerous and healthy brain tissue, they are addressing the largest long-standing issue of brain cancer treatment – effective, successful and safe surgical removal.

surgical guidance due to its non-invasive, cost-effective nature and its ability to produce 3D images in real time. In comparison to ultrasound imaging (also capable of 3D and real time data), OCT has a far superior resolution (0.04 vs 0.3 mm³) but a localised field of view (8–16 vs 12,500 mm³).

APPLICATION AND PROGRESSION OF OCT

Dr Xingde Li and Dr Alfredo Quiñones-Hinojosa are on the forefront of developing this important and promising intraoperative surgical imaging technique. They have taken their research to the next step, by assessing the scope of OCT to distinguish between cancerous and non-cancerous brain tissue. This underlined the importance and potential of OCT in clinical applications, and Dr Li and Dr Alfredo Quiñones-Hinojosa recently received a National Institutes of Health (NIH) grant to further develop this method for intra-operative use.

In their initial study in 2015, Dr Li and Dr Quiñones-Hinojosa reported that OCT can distinguish between cancerous and non-cancerous tissue with much increased sensitivity and specificity, in comparison to ultrasound. These results were determined by studies on brain tissues from patients with cancerous and non-cancerous (seizure) brain pathologies, as well as *in vivo* studies in mice implanted with glioblastoma cell lines from human patients.

effective form of treatment and is central to improving prognosis of patients with this type of brain cancer. Considering this, it is vital that imaging techniques used in surgery are robust and accurate. Although current technologies, such as MRI, ultrasound and fluorescence labelling, have contributed to advances in resection surgery accuracy, each have their functional advantages and disadvantages and can often be cumbersome, invasive, costly or even physiologically impractical.

SHEDDING LIGHT ON PROCEDURES

Optical coherence tomography (OCT) is an effective biological imaging technique based on principles similar to ultrasound, utilising light as opposed to sound waves to reflect varying optical densities of target material. Originally utilised to study the retina, OCT has been used to image many organs including the gastric tract, coronary arteries, breast tissue, and most recently it has been used to image the brain. OCT has been used for 2D and 3D imaging of *ex vivo* human brain cancers and is an attractive approach for

Optical coherence tomography is an extremely effective biological imaging technique utilising light to reflect varying optical densities of target material

Brain cancer has a poor prognosis. Ultimately it is fatal due to two facts: it disrupts functional brain tissue and it is difficult to perform brain cancer surgery without injuring normal eloquent brain tissue.

BRAIN SURGERY – NOTORIOUSLY TROUBLESOME

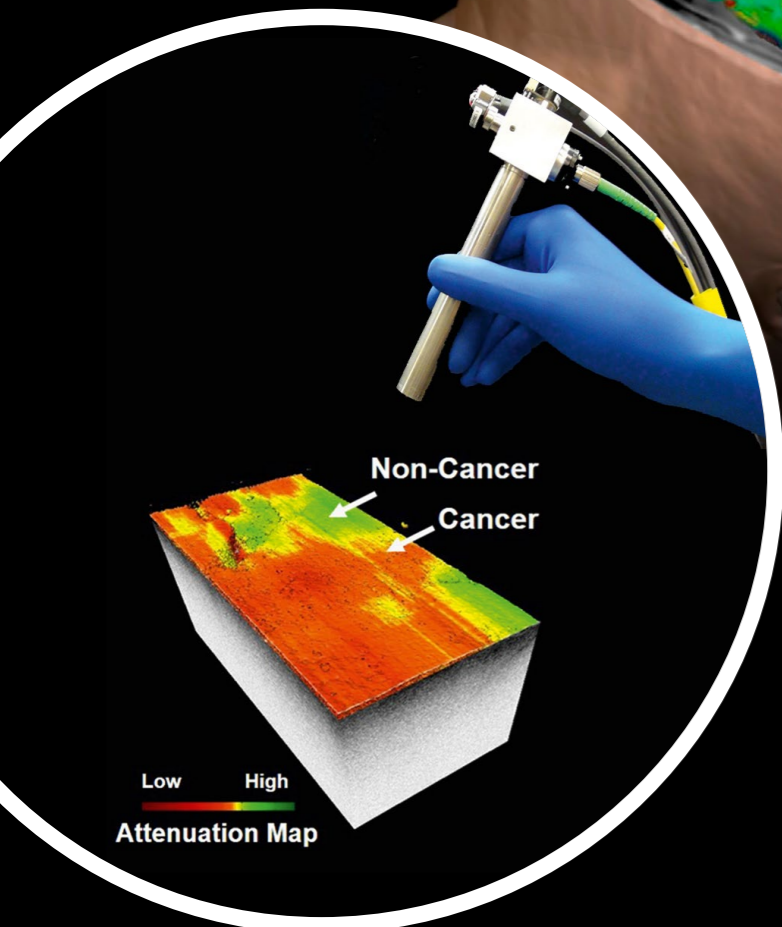
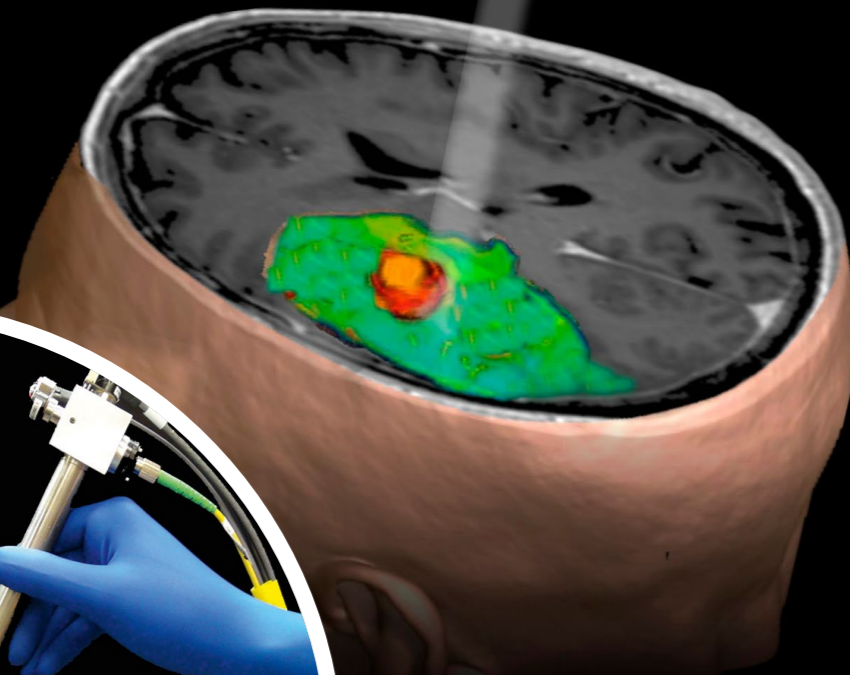

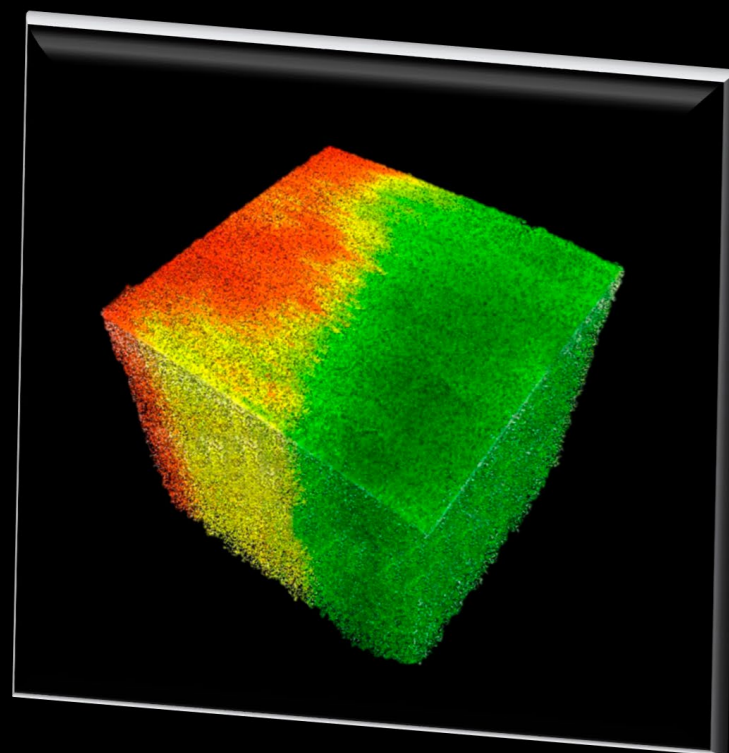
During brain surgery, neurosurgeons face an age-old struggle: this ‘struggle’ comes from the need to minimise brain injury at the same time removing as much brain cancer tissue as possible.

Studies have shown that there is a 160–200% increase in survival of patients who receive successful gross total resection of the lesion as seen by imaging such as Magnetic Resonance Imaging (MRI). Patients who experience post-surgery deficits, however, have a 25% lower survival rate compared to those without such surgical complications, regardless of the extent of the resection. So, while surgeons must attempt to remove the whole cancerous lesion to improve survival, any extraneous tissue damage will in fact reduce survival and must therefore be minimised.

The most common primary brain cancer is called glioblastoma – a cancer of the glial cells which are found throughout the brain. Intraoperative analysis and visualisation of the borders between cancerous and normal tissue is unreliable with the current technologies available but brain surgery remains the most

Traffic Lights for Brain Cancer Resection
Optical Coherence Tomography (OCT) can distinguish cancer (red) from non-cancer (green) tissues in *in vivo* rodent models of human brain cancer and *ex vivo* fresh human brain cancer specimens with high sensitivity and specificity (Kut et al.).

This image captures the translational nature of this technology, and includes the OCT imaging probe (pointing over the region of interest as shown in the reconstructed, pre-operative MRI image) and the 3D optical property map obtained from a high-grade brain cancer patient.



© Carmen Kut, Jordina Rincon-Torroella, Alfredo Quiñones-Hinojosa, Xingde Li


DISTINGUISHING THE GOOD, THE BAD AND THE UGLY

OCT is effective in distinguishing cancerous tissue from healthy brain cells by assessing and comparing the levels of reduction of the signal projected by the OCT light source. In other words, how much the OCT signal is attenuated depends on the tissue involved (i.e., cancer cells, white matter or grey matter). Dr Li and his team found that the optical attenuation was lowered more by cancer cells than white matter, and that grey matter (darker brain tissue) was lower than that of cancer cells – enabling distinction between all three tissues using OCT. No significant distinction was observed between the cancer core and infiltrated zones, allowing an overall comprehensive view of the affected area needing to be resected in surgery.

Due to the presence of myelin within white matter (unseen in grey matter), and the degradation of this myelin by infiltrating cancer cells, OCT signal attenuation varies across these tissue types. It is this myelin presence which dictates the differing degrees of signal attenuation – a noticeable trend across the three tissue types. At roughly 100–200 frames per second, OCT data can be acquired, processed and displayed in one to two seconds for an 8–16 mm³ volume. These factors demonstrate that it represents a robust and reliable method of viewing cancers amongst brain tissue in real time with little problematic disturbance from additional pathological variables. The degree of signal attenuation can be colour-coded in red (cancer) and green (non-cancer) over the surface of the imaged tissue volume, providing direct visual cues to the surgeon for resection in real time. The results of this work demonstrate that OCT provides a unique quantitative approach to evaluating tissue type (cancer vs grey matter vs white matter) in real time, eliminating the need for interpretation by the operating neurosurgeon when making decisions regarding which areas to remove during surgery.

Dr Li and Dr Quiñones-Hinojosa's work demonstrates that optical coherence tomography provides a unique quantitative approach to visually evaluating brain tissue type in real time during brain surgery

Dr Xingde Li's group developed a home-built and high-speed OCT imaging system for label-free, real-time and quantitative imaging of human brain cancer tissues, while Dr Alfredo Quiñones-Hinojosa's group provided the clinical expertise and novel animal models, including rodents implanted with human brain tumors using a patient-derived brain tumor initiating cell line (BTIC).



© Carmen Kut, Jiefeng Xi, Jordina Rincon-Torroella, Alfredo Quiñones-Hinojosa, Xingde Li

ONWARDS AND UPWARDS

Current studies by Drs Li and Quiñones-Hinojosa aim to continue systematically evaluating the accuracy and clinical significance of OCT for brain cancer imaging. Overall, *ex vivo* tissue samples from about 60 human patient brains have been processed alongside mice brains *in vivo*, using OCT to look at high- and low-grade gliomas. Histological analysis of the brain tissues has also been performed with these tissue samples acting as the "gold standard" to which the data acquired from OCT will be compared against. This, in turn, enables statistical assessment of OCT's accuracy and information potential.

Drs Li and Quiñones-Hinojosa plan to improve the OCT approach in glioma imaging and intraoperative imaging during brain surgery. They plan to refine the diagnostic signal attenuation thresholds that distinguish between tissue types, as well as the speed at which the data images are collected and projected, improving both spatial and temporal parameters of OCT imaging of brain cancers. From this, Dr Li and his team hope to

further develop and validate in the operating room with patients the colour-coded map of brain tissue from OCT data, distinguishing between grey matter, white matter and cancer. This will provide visual cues for neurosurgeons to guide their cancer resection process, quantitatively, reliably and robustly – vastly improving the effectiveness of surgery technique and patient outcome.

This is an extremely exciting methodology, and its practice will no doubt lead to further advances in brain cancer resection. Deeper analysis of information will also be explored to highlight how data can be most efficiently used, with one example being major blood vessel proximity – preventing bleeding or stroke-related complications during surgery. Based on the positive preliminary results from *ex vivo* human brain cancer tissue and *in vivo* mouse brain cancer model imaging studies, Drs Li and Quiñones-Hinojosa recently launched pilot procedures of OCT usage during human brain surgery – a break-through step for this intra-surgical guidance method. Near future plans include using intraoperative OCT in 30 patients with low-grade gliomas, and 30 patients with glioblastomas. Data produced in these pilot studies will not impact clinical decisions or standard of care, and risk to patients is thought to be minimal.

OCT provides a real-time, non-labelling, cost-effective method for intra-surgically guiding brain cancer tissue removal. There is no doubt that the discoveries of Drs Li and Quiñones-Hinojosa and their collaborators will open many doors to cancer patient treatments, prognosis in the brain, and beyond.

Q&A

When did you start looking at the potentials for OCT methods, and did you expect the success of your results so far?

We began looking at the potentials of OCT for brain applications in 2011. It began as a research project for Dr Carmen Kut (a first-year PhD student at the time), who started to look at OCT images of freshly resected human brain cancer specimens (obtained from the operating room). However, we did not realise the full potential of the technology until two years later in 2013, once we had collected data from multiple patients and conducted the quantitative analyses (thus realising that OCT is capable of differentiating brain cancer from non-cancer with high sensitivity and specificity).

What proportion of brain cancer patients will undergo resection surgery?

Patients with glioma have finite survival times and surgery is the first-line therapy. The median survival time for patients with grade IV glioma (i.e., glioblastoma) is approximately 14 months. There is a growing body of evidence showing that the extent of resection (EOR) is the most important risk factor associated with delayed tumour recurrence and prolonged survival (Chaichana, Kaisorn L., et al., "Establishing percent resection and residual volume thresholds affecting survival and recurrence for patients with newly diagnosed intracranial glioblastoma." *Neuro-oncology* 16.1 (2014)). Due to the high recurrence rate and poor prognosis, it becomes even more critical to be able to differentiate between cancer and normal brain tissues in real time during surgery in order to maximise EOR while minimising collateral damage to healthy tissue.

What proportion of patients that do undergo brain cancer resection experience surgery related deficits and what proportion are cognitive?

In one of our own studies, out of 306 patients with glioblastoma, 11% developed surgery-related motor or language deficits. We also found that patients who incurred surgery-incurred deficits have a 25% decreased median survival than patients without deficits, regardless of extent of resection. (McGirt, Matthew J., et al.

"Association of surgically acquired motor and language deficits on overall survival after resection of glioblastoma multiforme." *Neurosurgery* 65.s3 (2009))

Is there potential for the cancer itself to cause brain damage to patients and is surgery advised against if this is the case to avoid further damage?

Yes, brain cancer can invade critical areas e.g., speech, motor and sensory areas. In this case, it is not always possible to resect these critical regions (even if cancer is present). In cases where brain cancer involves critical speech areas, we can perform "awake craniotomies" where the patient is awake during surgery. This is because we need to use special language mapping techniques (by applying mild electrical currents to the brain while the patient performs tasks e.g., speech). If the stimulation prevents the patient from speaking or performing other critical functions such as moving the face, arm, or leg, that area of the brain is preserved (regardless of cancer involvement). In fact, there are cases when patients play guitar and perform other feats during brain cancer surgery. <https://www.theguardian.com/world/video/2015/jun/04/man-plays-guitar-conscious-brain-surgery-video>

Could OCT provide a platform for robust interpretation of other pathologies to aid treatment?

Definitely. OCT was first used to detect retinal pathologies. It is now routinely used in ophthalmology clinics and, furthermore, is FDA approved for ophthalmic, gastrointestinal and intravascular applications. It is an exciting imaging technology with many exciting developments and clinical trials in multiple clinical specialties. Due to the fact that we invented new devices with new mathematical algorithms, we can now use this new and improved OCT technology in intra-operative studies in brain cancer. We plan to expand our methods into other clinical applications such as head and neck cancer in the near future.

Detail

RESEARCH OBJECTIVES

Dr Li and Dr Quiñones-Hinojosa's research focuses on glioma – the most common adult primary brain cancer. Their latest study aims to develop an imaging method to distinguish between cancerous and non-cancerous brain tissue.

FUNDING

National Institutes of Health (NIH)

COLLABORATORS

- Dr Carmen Kut
- Dr Kaisorn L. Chaichana
- Dr Jiefeng Xi
- Dr Shaan M. Raza
- Dr Xiaobu Ye
- Dr Elliot R. McVeigh
- Dr Fausto J. Rodriguez
- Dr Alfredo Quiñones-Hinojosa, MD
- Laboratory of Biophotonics Imaging Technologies (BIT)
- Department of Biomedical Engineering, Johns Hopkins
- Department of Neurosurgery, Johns Hopkins
- Division of Neuropathology, Johns Hopkins
- Department of Neurosurgery, Mayo Clinic, Jacksonville, Florida

BIO

Dr Xingde Li is a professor in the Department of Biomedical Engineering at Johns Hopkins. He is the head of the Laboratory of Biophotonics Imaging Technologies (BIT) which specialises in developing cutting-edge and translational bio-photonics imaging technologies that interface and bridge basic engineering research with clinical diagnosis and interventions.

CONTACT

Xingde Li, PhD
Fellow of OSA, SPIE and AIMBE
Professor, Dept of Biomedical Engineering
Johns Hopkins University
720 Rutland Avenue, Traylor 710
Baltimore, MD 21205
USA

E: xingde@jhu.edu
T: +1 410 955 0075
W: <http://bit.bme.jhu.edu/Home.php>